

# Pleural-cutaneous fistula 52 years after oleothorax

Graça Pires\*, Maria José Goes\*\*, Vasco Geraldès\*\*\*, Jorge Rodrigues\*\*\*\*, João Rolo\*\*\*\*\*, António Castro\*\*\*\*\*

### Abstract

Oleothorax was largely used from 1930 to 1950 in the treatment of pulmonary tuberculosis (PTB). Although it has been discontinued since the 1950's, mainly because of the success of chemotherapy and the thoracic surgery, complications have appeared many years later. The authors report the case report of an 80-year-old man,

with a previous history of PTB, treated 52 years previously with oleothorax, admitted to study a mass in the right supraclavicular region. Computed axial tomography revealed a pleurocutaneous fistula. Aspiration revealed Key words: oleothorax, pleurocutaneous fistula, tuberculosis.

### Introduction

Introduced by Bernou in 1922, oleothorax was a type of lung collapse therapy used in the treatment of pleural-pulmonary tuberculosis. It consisted of introducing an oil into the pleural cavity (paraffin, olive oil, or mineral oil), combined with an antiseptic substance (gomerol).

It was indicated in situations of persistent tuberculous empyema, for the prevention of symphyseal processes, and for the obliteration of pleural-cutaneous fistulas.<sup>1,2,3,4</sup>

The introduction of a gomenolated oil into the pleural cavity often led to complications, including situations of acute pleural inflammatory reaction, accompanied by general symptoms, probably related to the antiseptic, which in some situations required its removal and created more severe complications, such as the formation of pleural-pulmonary fistulas and pulmonary edema that was sometimes fatal.<sup>3</sup>

The oil introduced (500 ml to 1000 ml) was supposed to be removed 18 to 24 months later,<sup>5</sup> but this was not always done because the clinical improvement obtained led to the medical care being abandoned. Although this practice was abandoned in the 1950s due to the therapeutic success of antibacillary agents and new surgical perspectives, several decades later, complications continued to emerge, such as bronchopleural and pleural-cutaneous fistulas, recurrent bacterial empyemas (by *Haemophilus Influenza* and by *Mycobacterium tuberculosis*) and pleural calcifications.<sup>6,7,8,9,10</sup>

The authors present the clinical case of a patient whom they observed recently, with a very rare complication due to therapeutic oleothorax performed several decades earlier.

### Case Report

Male patient, aged 80 years, with a history of pleural-pulmonary tuberculosis at the age of 27, when he was treated with oleothorax and was cured as a result. He remained asymptomatic until the age of 79, when he noticed a slow-growing tumefaction in the right infraclavicular region, which was slightly painful, and without skin manifestations. He reported no respiratory or systemic symptoms. In the physical examination, a tumor of around 12 cm in diameter was observed, in the right infraclavicular region, with elastic consistency, painless, and without skin changes (Fig. 1). The patient's general health was good, no enlarged lymph nodes were felt on palpation, and semiology of the respiratory apparatus did not reveal any changes. The laboratory tests: hemogram, proteinogram and hepatic function, and sedimentation rate, did not show any significant changes, and the

\*Resident to the Immunoallergology Supplementary Internship

\*\*Resident to the Internal Medicine Supplementary Internship

\*\*\*Surgery Interim Assistant

\*\*\*\*Radiology Hospital Assistant

\*\*\*\*\*Internal Medicine Hospital Assistant

\*\*\*\*\*Head of the Internal Medicine Service

Medicine 2 Service of the Hospital de Santo António dos Capuchos, Lisbon

Received for publication on the 15<sup>th</sup> Nov 97

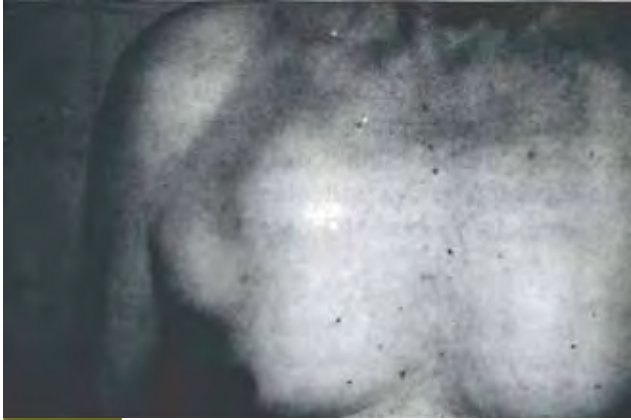

FIG. 1

tumor markers (AFP CEA, CA19.9) were negative. Chest X-ray showed an area of opacification with clearly-defined edges on the outer surface of the right upper hemithorax (Fig. 2). Computed axial tomography of the chest showed a lesion in the right pleural cavity, which extended through the intercostal space to the soft tissues of the anterior thoracic wall (Fig. 3). Aspirative biopsy of the tumor was carried out, and an oily liquid was extracted, which on analysis, proved to be a mineral oil. The cultures were negative for bacterias, micobacterias and fungi, and the cytology test was also negative. Several aspirations were performed, and the lesion gradually decreased in size. The patient remained clinically well after 15 months.

### Discussion

Pleural-cutaneous fistulas are among the late complications of oleothorax therapy, and can appear many years after the initial therapy, generally accompanied by reactivation of the tuberculous empyema and abscess of the thoracic wall.<sup>7,9</sup> Forouhi et al.<sup>6</sup> describe the case of a patient with tuberculous empyema that appeared 62 years after receiving oleothorax to treat pulmonary tuberculosis, making this the most delayed complication published to date. Fistulas may be associated with empyema by *Haemophilus influenzae*.<sup>8</sup> In the patient studied, the liquid extracted from the tumefaction on the thoracic wall was sterile, which, associated with the absence of inflammatory signs in the above-mentioned lesion, ruled out any infection. Hutton<sup>7</sup> reports that an expansion of an oleothorax can expand many years later, without reactivation of the tuberculous process, but merely due to the irritant effect of the oil introduced into the pleural cavity. This

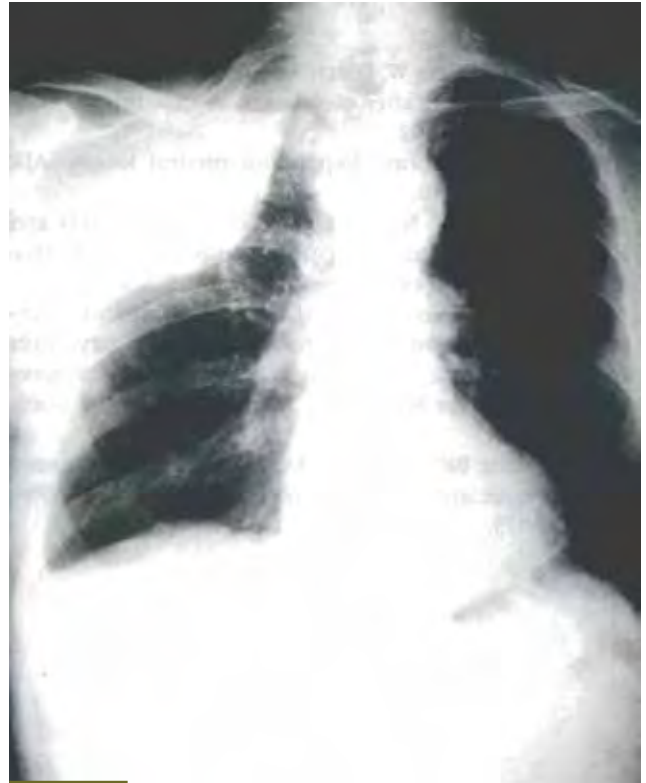


FIG. 2

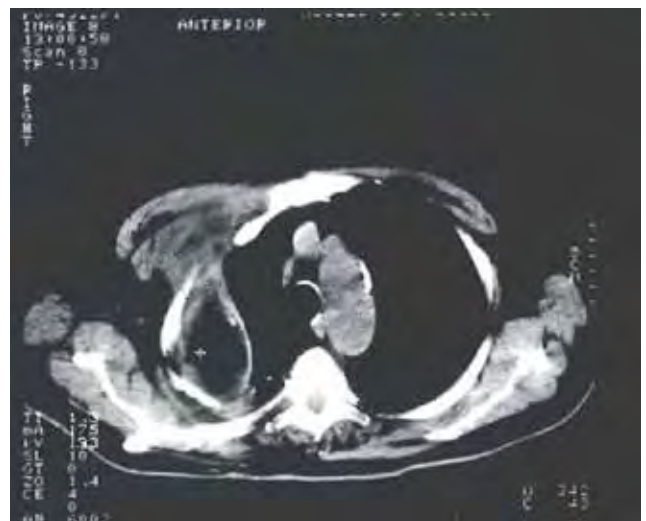

FIG. 3

process may be rapid, causing respiratory difficulty, or it may be gradual, and asymptomatic. This patient presented a build-up of fluid in the thoracic wall, after an asymptomatic period of 52 years. Of particular interest is the fact that these symptoms appeared without progression of the underlying disease and

without a history of recent thoracic trauma that may have contributed to the appearance of the fistula. ■

## References

1. Tapia M, Quintela L, Ferraz-Carvalho A. La conversión del Neumotorax en Oleotorax. El Neumotorax Extrapleural. Editora Luso-Espanhola 1947 cap VIII: 147-153.
2. Dumarest F, Mollard H, Lefèvre P, Germain J. L'Oléothorax. La pratique du Pneumothorax Thérapeutique. Editora Masson cap II: 349-354.
3. Dumarest F, Berret B. Oleothorax et lavages pleuraux. La pratique du Pneumothorax thérapeutique et de la collapsothérapie chirurgicale. Editora Masson, 3rd edition 1929, cap IV: 214-222.
4. Sylla A. Oleotórax. Patología y Clínica de las Enfermedades del Aparato Respiratorio (Tuberculosas y no Tuberculosas). Editora Manuel Marín 1947:551-553.
5. Browning RH, Ray ES, Rotenberg L. Oleothorax. A re-evaluation with a final report of 101 cases. Am Ver Respir Dis 1946;54:122-127.
6. Forouhi NG, Walker W, Leitch AG. Tuberculous empyema presenting 62 years after oleothorax. A case report. Resp Med 1994;88: 391-392.
7. Hutton L. Oleothorax. Expanding pleural lesion. AJR 1984;142: 1107-1110.
8. Tsou E, Yeager H, Katz S. Late bronchopleural fistula and Hemophilus influenzae empyema longstanding oleothorax – report of two cases. Chest 1978; 74: 573-575.
9. Jost A. Complications très tardives de pneumothorax extrapleuraux par fistulisation externe (sur billes d'acryl après 18 ans) ou interne (sur oléothorax, respectivement après 32 et 48 ans). Ver Med Suisse Romande 1986; 106: 605-617.
10. Deboisblanc BP, Buechner HA, Haponik EF. Computed tomographic appearance of an oleothorax. Thorax 1988; 43: 572-573.