

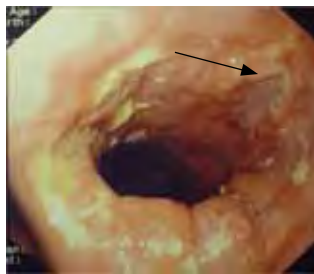Sodium Bicarbonate and duodenal ulcer: consequence of an inadvertent treatment

Sónia Carvalho, Sandra Tavares, Rui Couto, Fernando Guimarães

A male patient, aged 57 years, was admitted with severe metabolic alkalosis. For 15 years, he had had diarrheic excretions of semi-liquid feces, sporadic food vomiting, paraesthesias and tetanus affecting the hands. The patient reported epigastralgia evolving for months, alleviated with meals and with sodium bicarbonate, which he had acquired “by grams” sic., at the pharmacy. In analytical terms, besides the metabolic alkalosis (pH 7.61 mmHg, paCO_2 65 mmHg, paO_2 53, $\text{CO}_3 > 60$ mmol/L) hypokalemia, hypochloremia and acute renal dysfunction were observed (136 mmol/L; K 2,3 mmol/L; Cl 4,4 mmol/L; creatinine 3,9 mg/dL; urea 60 mg/dL). Upper digestive endoscopy revealed the presence of peptic esophagitis and an active duodenal ulcer of 15 mm in diameter (A). The patient presented favorable evolution, with clinical evolution and regression of the above-mentioned alterations, reflected in the acid-base nomogram – based on the day of admission and on the two subsequent days (shown in figure 2 in red circles 1, 2, and 3).

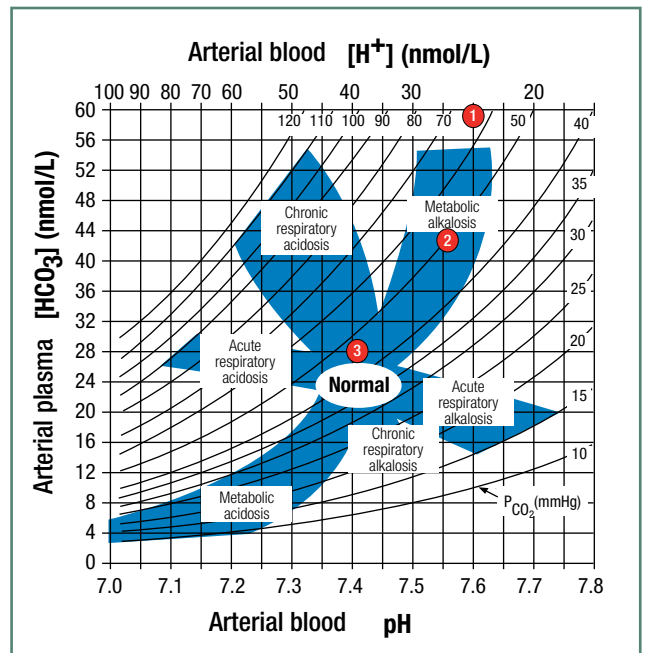
Metabolic alkalosis is a relatively common disorder, characterized by an increase in arterial pH, serum bicarbonate, and partial CO_2 pressure.

The excessive administration of alkalinizing agents may be accompanied by metabolic alkalosis, particularly where renal elimination



Active duodenal ulcer (arrow).

FIG. 1



1-4/4/07; 2-5/4/07; 3-6/4/07.

FIG. 2

is impaired.

The association between the use of antacids in the treatment of peptic ulcer and the symptoms of metabolic alkalosis goes back to 1915.¹ For years, it was recognized as a complication of the treatment of peptic ulcer.²

Despite the current rarity of this association, it should not be ignored in the differential diagnosis of situations of metabolic alkalosis. ■

References

1. Cooke AM. Alkalosis occurring in the alkaline treatment of peptic ulcers. QJM 1932; 1:527-541.
2. Wesley Eisele C. Changes in the acid-base balance during alkali treatment for peptic ulcer. Arch Intern Med 1939; 63 (6):1048-1067.

Vila Real Hospital – Hospital Centre of Trás-os-Montes and Alto Douro

Received for publication on the 31st August 2009

Accepted for publication on the 12th October 2010