

Porencephaly: A propos of two clinical cases

Anabela Nunes*, Manuel Gonçalves**, Victor Gomes***

Abstract

The authors present a two case report of the Porencephaly. They make considerations on clinical features, differential diagnosis and therapeutic.

Key-words: porencephaly; neurologic disturbances; "pore"

Introduction

Heschl,¹ in 1859, in a study of patients with alterations in the embryonal development and/or congenital malformations, has detected encephalic lesions he designated as *Porencephaly* (from "pore" or "hole"). Since then this expression has generated some controversy in its characterization and definition, and throughout the years a number of denominations have emerged in the medical literature for this very same pathology:²

- 1 – "Porencephaly" (Heschl, 1859);
- 2 – "Encephalomalacia" (Kundrat, 1882);
- 3 – "Typical Porencephaly" (Ernst, 1909)
- 4 – "Porencephaly due to a phlebothrombosis and a phlebostasis" (Marburg et al, 1945);
- 5 – "Schizencephaly" (Yakovlev and Wadsworth, 1946):
 - "Schizencephaly without hydrocephaly"
 - "Schizencephaly with hydrocephaly"
- 6 – "True Porencephaly" (Gross and Kaltenback, 1960);
- 7 – "Porencephaly associated with chromosomal anomalies" (Book and Santesson, 1960);
- 8 – "Porencephaly associated with polymicrogyria" (Dekaban, 1965);
- 9 – "Familiar Porencephaly" (Warkany, 1971);

More recently and accepted by consensus is the

Koreaki Mori definition,² describing PORENCEPHALY as the presence of "intraparenchymal cavities (simple or multiple) at cerebral hemispheres level, filled with cerebrospinal fluid, that communicate with the ventricle and/or the subarachnoid space".

This definition enables to include two types of etiopathogenic different conditions: the true or congenital porencephaly, and the encephaloclastic or acquired porencephaly.

Congenital conditions are rare and are set in a sequence of anomalies in the embryo development or in intra-uterine vascular accidents.^{6,9} Acquired conditions, which are the most common forms, can emerge after several clinical conditions, among which the most commonly described are:

- Traumatic lesion (whether or not peri-natal);
- Inflammatory lesion (meningitis, cerebritis, ventriculitis);
- Cerebrovascular accident (ischemic, hemorrhagic);
- Surgery (ventricular puncture or drainage);
- Hydrocephaly and encephalocele.

The authors present two clinical cases which are an example of these etiopathogenic possibilities.

Case 1

LMMS, 28 years old, male gender, white Caucasian, dependent on others, natural and resident in Lisbon.

Clinical Condition:

Labor Dystocia (use of Forceps)

Congenital left hemiparesis

Severe psychomotor retardation (oligophrenia)

Generalized convulsive crisis since the age of 10 years old, resisting multiple therapies previously administered (no reference to epileptic seizures of focal characteristics; EEG showed generalized paroxysmal changes although asymmetric, by depression of the

*Resident to the Internal Medicine Supplementary Internship

**Resident to the Neurology Supplementary Internship

***Internal Medicine Senior Hospital Assistant

Medicine Service, Hospital S. Jose

Neurology Service, Hospital Sto Antonio dos Capuchos

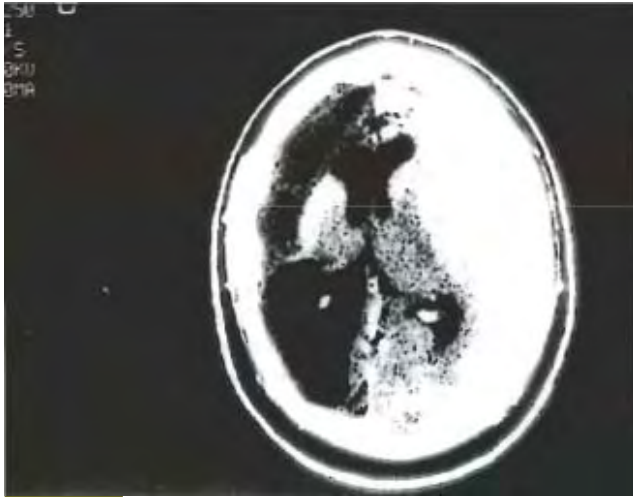


FIG. 1

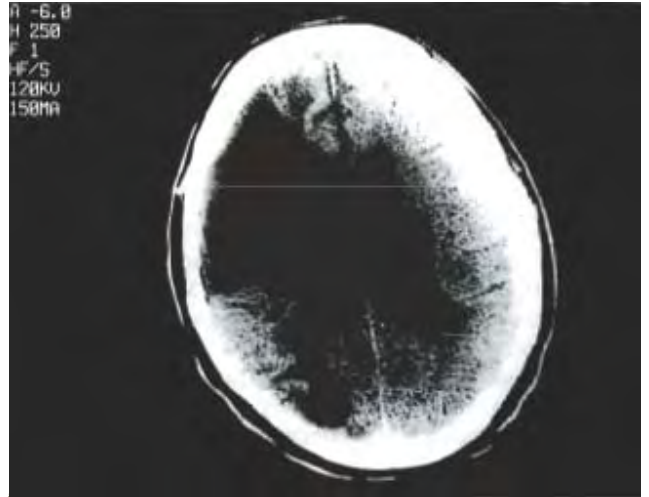


FIG. 3

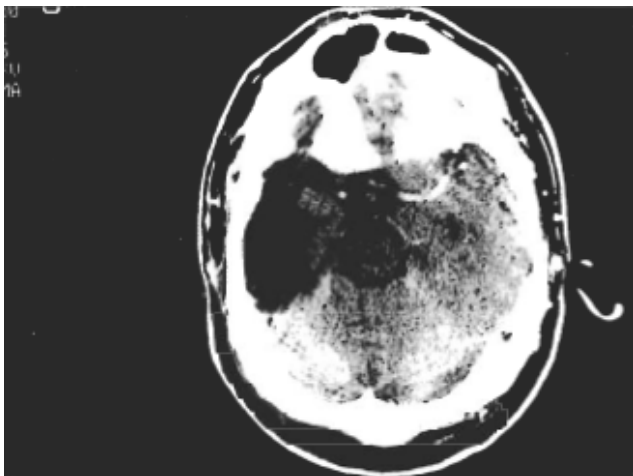


FIG. 2

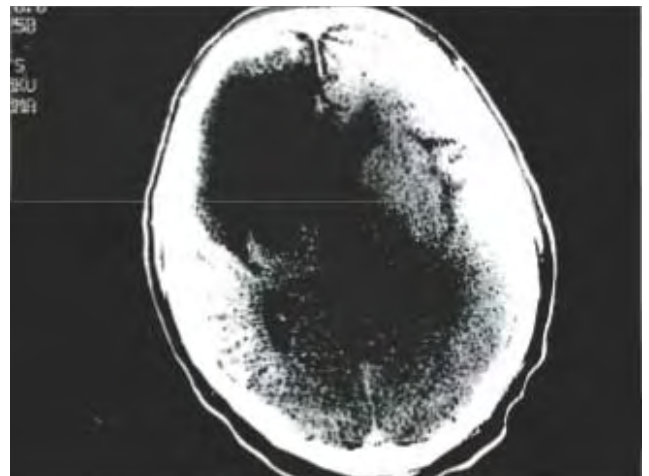


FIG. 4

traces at the right cerebral hemisphere level).

Referred for the first time to a Neurology appointment at 27 years of age, displaying convulsive crises with a bi-weekly frequency.

At present controlled with phenytoin (300 mg/day) carbamazepine (1200 mg/day) and vigabatrin (3000 mg/day);

A CE CT scan (Fig 1 and 2) revealed: “wide porencephalic lesion in the posterior first 1/3 of the right cerebral hemisphere; cortico-subcortical hypodense lesion in the anterior 1/3 of the same hemisphere; asymmetric ventricular dilation”

Case 2

JACS, 58 years, male gender, white Caucasian, stone-

mason, natural and resident in Lisbon.

Clinical Condition

Hypertension history since he was 45 years old

At 50 he presented an ischemic cerebral vascular accident at the level of the area of the tunica media cerebral arteries and posterior to the right (documented by a CE-CT-scan), from which emerged a left hemiparesis condition with a confusional syndrome.

At 58 he showed an ischemic vascular accident and non-characterized convulsive crisis (it was not possible to obtain more detailed data).

A month afterwards a new ischemic vascular accident on the left cerebral hemisphere (documented by a CE-CT scan), with a condition of right hemiparesis predominantly brachial and homolateral facial paresis.

For the screening of an eventual embolic source it was carried out an echocardiogram mode M and bi-dimensional, showing no changes.

At the end of a month there was a worsening of the clinical condition, evolving for coma and death afterwards.

The necropsy examination confirmed the clinical and imaging data.

The CE-CT scan (Fig.3 and 4) revealed: “wide porencephalic lesion in the anterior half of the right cerebral hemisphere, that communicates with the ventricular cavities, conditioning its dilation”.

Comments

Porencephaly manifestations lead to many diverse clinical conditions,⁴ and depend on the extension, the type of encephalic involvement and the time of its onset. Therefore, there may be present motor, sensorial or psychic changes.

In childhood⁶, it can manifest itself as a delay on the psychomotor development, by hemiparesis manifestations, unbalanced gait or convulsive crisis, as happened in the first clinical case. Another situation, potentially severe is the dysplastic Porencephaly (a form of congenital Porencephaly) characterized by a severe mental deficiency, and that those motor disturbances can evolve to a spastic tetraplegia or to the decerebration stiffness.

In what concerns the second case described, Porencephaly has evolved from a sequence of several and wide cerebral ischemic processes, with a consequent progressive deterioration of the neurologic condition.

On the other hand, the disturbances of the central nervous system are more severe when associated to hydrocephaly presence.

The diagnosis of such conditions must be formulated before a spastic hemiparesis condition or asymmetric macrocephaly in which the EEG reveals a unilateral depression of the electric activity.

Imaging⁶⁻⁸ contributes to clarify this nosological entity. Cranioencephalic computerized tomography (CE-CT scan)^{3,5} reveals one or more areas of lesions, occupying space, of low density, circumscribed and without capturing contrast (true “pores”). Sometimes there is a communication with the ventricles and/or the subarachnoid space, and the former may be dilated. This ventricular dilation is asymmetric and leads frequently to a deviation of the mean line of

the structures, what is a factor of a bad prognosis. Perilesional cerebral atrophy is another aspect that may evolve in association. It is a useful test in the differential diagnosis, particularly with the abscesses and the cystic tumors. In these, there is a clear contrast capture being evident nodular images of high density, or ring like deposits. Another exam, cerebral angiography, can complement such diagnosis, revealing that these lesions are not vascularised.

From a therapy point of view it is established that in a general way, the therapy is medical² and predominantly symptomatic, mainly in what refers to the control of the convulsive crisis (anti-epileptic crisis). There is only a place for a surgical therapy in situations where there is hydrocephaly, a marked mass effect or a focus responsible for uncontrollable convulsive crisis and resistant to therapy. In patients with a surgical indication, the option varies according to the clinical condition and the extension of the lesion, from a trepanning to an immediate decompression, to placing a ventricle-peritoneal derivation.

In conclusion, these situations are irreversible and usually severe, as it is characterized by real losses of the central nervous tissue, which is not liable to be recovered. It is crucial, therefore, to have in mind such concepts, with a view to the diagnosis and effective therapy of the complications of medical and/or surgical character that can be associated. ■

References

1. Heschl R. Gehirndefekt und Hydrocephalus. *Vjschr. Prakt. Heil. Prag* 1859; pp 61-59.
2. Mori K. Anomalies of the Central Nervous System. *Neuroradiology and Neurosurgery*. Thieme-Stratton Inc 1985.
3. Gastaut H, Cedra M, Michel B. Bilateral and Symmetrical porencephaly in neonates revealed by computerized tomography. *Advances in Neurology*, 1979; 25: 199-209.
4. Naef B W. Clinical features of porencephaly: a review of thirty two cases. *Arch Neurol Psychiatry* 1958; 80: 133-147.
5. Ramsey RG, Hackman MS. Computed tomography of porencephaly and other cerebrospinal fluid-containing lesions. *Radiology* 1977; 123:73.
6. Warkany J. Congenital porencephaly and schizencephaly. *Malformations of the Central Nervous System*. Chicago, Year Book 1971; pp 246.
7. Newton TH, Potts DG. *Radiology of the Skull and Brain*. Ventricles and Cisterns, the Mosby Company 1978; 4.
8. Raybaud C. Destructive Lesions of the Brain. *Neuroradiology* 1983; 25: 265-291.
9. Barcovich AJ. *Pediatric Neuroimaging*. Raven Press 1990.